



**PATIENT**

Savannah Standish

**SPECIES**

Canine

**BREED**

Mix

**SEX**

Female Spayed

**AGE**

11 years

**WEIGHT**

55.2lbs

**INTERPRETED BY**

Maggie Machen Lamy,  
DVM, DACVIM  
(Cardiology)

**IMAGING PERFORMED BY**

Kelly Vazquez, CVT

**HOSPITAL NAME**

The Venturing Vet

**REFERRING VET**

Dr. Herzog

**INVOICE**

21752

**DATE**

10/28/21

**PRESENTING CLINICAL SIGNS**

History: Patient presents for arrhythmia. Current medications: Denamarin.

-Abnormal PE/Chem/CBC/UA Results: ALT263, Alk. Phos. 2587, cholesterol 352, platelet count 464.

**ECHOCARDIOGRAM FINDINGS**

2D, m-mode, color flow and doppler imaging is available. Mild thickening of the mitral valve leaflets with no prolapse into the left atrial lumen. Trace/mild central mitral regurgitation with a normal left atrial dimension. Normal LV diameter with adequate myocardial function. The tricuspid valve appears mildly thickened with trace/mild tricuspid regurgitation. Normal right atrial and ventricular diameter and morphology indicating no overt evidence of pulmonary arterial hypertension. The pulmonic and aortic valves are normal in morphology and mobility. Normal pulmonic and aortic outflow velocities with laminar flow. No obvious aortic or pulmonic

**CARDIAC CHART**

CANINE CARDIAC PARAMETERS	MR VMAX (m/s)	TR VMAX (m/s)	LA/AO (Boon method)	LA/AO (Heart Base; Swe)	FS (%)	EF (%)	EPSS (cm)
<b>NORMAL PARAMETER</b>	4.5-5.5	<2.7	1.3	<1.6	28-40	40-100	<0.6
<b>PATIENT</b>	NM	NM	NM	1.2	28	54	0.54
CANINE CARDIAC PARAMETERS	HR (BPM)	AV VMAX (m/s)	PV MAX (m/s)	BODY WEIGHT (kg)	LA 2D short axis Base view (cm)	LVIDd Avg; 2D and m-mode short axis (cm)	LVIDs Avg; 2D and m-mode short axis (cm)
<b>NORMAL PARAMETER</b>	50-100	0.7-1.7	0.7-1.6	BELOW	BELOW	BELOW	BELOW
<b>PATIENT</b>	104	1.6	1.6	25.0	2.4	4.5	3.2
*Normal chamber parameters expressed as a mean value (SD)				3	1.27 (5.3)	2.46 (2.46)	1.36 (5.5)
<b>BODY WEIGHT DEPENDENT PARAMETERS</b>				5	1.40 (4.5)	2.74 (5.2)	1.60 (4.7)
<i>*Note: All measurements based upon multi-modal images and methods. An average value is reported.</i>				10	1.50 (3.8)	3.27 (3.5)	2.06 (3.1)
				15	1.83 (2.0)	3.71 (2.4)	2.43 (2.1)
				20	2.02 (1.9)	4.14 (2.2)	2.80 (2.0)
				25	2.18 (2.4)	4.48 (2.9)	3.10 (2.5)
				30	2.33 (3.3)	4.83 (3.9)	3.39 (3.4)
				35	2.48 (4.3)	5.17 (5.0)	3.69 (4.5)
				40	2.62 (5.2)	5.48 (6.1)	3.96 (5.4)
				50	2.88 (7.1)	6.07 (8.3)	4.46 (7.4)

**INTERPRETATION OF THE FINDINGS & FURTHER RECOMMENDATIONS**

Overtly normal cardiac dimensions and function, with no obvious dysfunction or dilation of the left heart. Trace/mild leaks in the mitral and tricuspid valves may reflect early valve disease or may be physiologic in origin. Follow up is advised should a murmur be ausculted in the future. No other significant valvular leaks are visualized, and no evidence of pulmonary hypertension.

This study does not evaluate the reported arrhythmia and an extended ECG is strongly recommended. A holter monitor may be indicated pending results. Finally if an arrhythmia is in fact documented, no structural cardiac cause is seen here, and full systemic evaluation may be warranted.



**PATIENT**

Savannah Standish

Monitor for development of a heart murmur, cough, labored breathing, exercise intolerance or collapse episodes.

**SPECIES**

Canine

A recheck echocardiogram is recommended should a significant murmur develop, or signs of cardiac compromise be noted in the future.

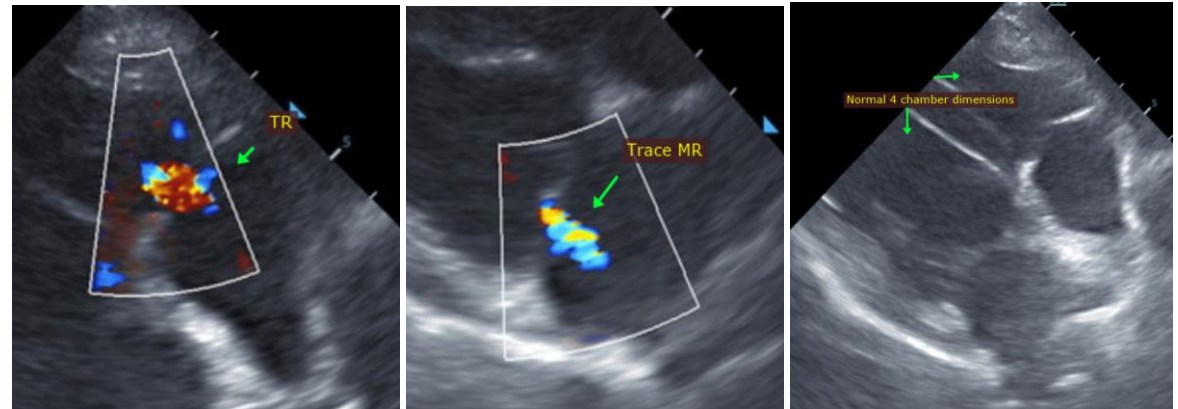
**BREED**

Mix

**IMAGES**

**SEX**

Female Spayed



**AGE**

11 years

**WEIGHT**

55.2lbs

The information and recommendations provided are based on the images presented by the referring veterinarian. No evaluation can be communicated regarding pathology that was not visible in the image/video clips provided.

**INTERPRETED BY**

Maggie Machen Lamy, DVM, DACVIM (Cardiology)

Thank you for this referral. This report was generated using transcription software, and minor dictation errors may be present. If the clinical or image interpretation does not parallel your findings or if I can be of any further assistance, please contact me.

**Maggie Machen Lamy, DVM**  
Diplomate of the American College of Veterinary Internal Medicine (Cardiology)  
info@sonopath.com

**IMAGING PERFORMED BY**

Kelly Vazquez, CVT

**HOSPITAL NAME**

The Venturing Vet

**REFERRING VET**

Dr. Herzog

**INVOICE**

21752

**DATE**

10/28/21